

Research Article

Infantile Acute Subdural Hematohygrogram: A Clinical and Neuroimaging Analysis of 18 Cases

Nobuhiko Aoki^{1, 2, *}

¹Department of Neurosurgery, Bethlehem Garden Hospital, Tokyo, Japan

²Department of Neurosurgery, Tokyo Metropolitan Tama Medical Center, Tokyo, Japan

Abstract

Objective: Even after the advent of magnetic resonance imaging (MRI), few studies have focused on the clinical profiles and neuroimaging characteristics of acute subdural hematohygrogram (ASDHy) in infants. The present study attempted to elucidate the pathogenesis of ASDHy by analyzing the clinical and neuroimaging findings of ASDHy. **Materials & Methods:** The subjects were 18 patients (eight males and ten females) younger than 2 years with ASDHy. Their median age at diagnosis was 3.8 months (range: 2-10 months), and 15 (83%) were younger than 4 months. Imaging studies found no evidence of any primary brain injury. **Results:** Five patients experienced a fall, and 13 (72%) had no history of head trauma. The presenting symptoms and signs were the acute onset of generalized convulsive seizures and or repeated vomiting. Retinal hemorrhage occurred in 14 patients (78%). The imaging studies revealed a large amount of bilateral, subdural fluid collection with an intensity higher than that of cerebrospinal fluid on MRI. Benign enlargement of the subarachnoid space (BESS) was found in 14 patients (78%), an enlarged sylvian fissure (LSF) was found in all the patients (100%), and greater, left-sided enlargement was evident in 16 patients (89%). Two patients underwent subdural drainage, and 16 patients (89%) were conservatively managed. All the patients had a favorable outcome. **Conclusions:** ASDHy is a self-limiting disorder associated with retinal hemorrhage and a benign clinical course. Most cases develop in early infancy. LSF presumably loosens the tight fixation of the temporal lobes at the middle cranial fossa, thereby increasing the rotational force of the brain even during mild or unnoticeable impacts. Increased cranio-cerebral disproportion, including BESS and LSF, is a structural vulnerability which can lead to ASDHy in early infancy.

Keywords

Acute Subdural Hematohygrogram, Infantile Acute Subdural Hematoma, Shaken Baby Syndrome, Abusive Head Trauma, Benign Enlargement of Subarachnoid Space, Large Sylvian Fissure, Structural Vulnerability

1. Introduction

The definition of acute subdural hematohygrogram (ASDHy) is very ambiguous, and few studies have discussed its pathogenesis [1]. Thus, the medical significance of ASDHy is still a matter of debate and uncertainty. The extra-axial fluid collection seen in the condition makes it possible to differen-

tiate it from a chronic subdural hematoma, subdural fluid collection, and benign enlargement of the subarachnoid space (BESS) using magnetic resonance imaging (MRI) [2]. However, even with the help of MRI, research has been unable to clarify the pathophysiology of ASDHy [1, 3], which theoret-

*Corresponding author: aoki.bb@jiseikai.jp (Nobuhiko Aoki), naoki_6217@yahoo.co.jp (Nobuhiko Aoki)

Received: 25 January 2024; **Accepted:** 12 February 2024; **Published:** 27 February 2024



Copyright: © The Author(s), 2024. Published by Science Publishing Group. This is an **Open Access** article, distributed under the terms of the Creative Commons Attribution 4.0 License (<http://creativecommons.org/licenses/by/4.0/>), which permits unrestricted use, distribution and reproduction in any medium, provided the original work is properly cited.

ically originates in tearing of the arachnoid membrane, allowing cerebrospinal fluid liquid to flow out of the subarachnoid space (SAS) into the subdural space [4].

However, there are still unresolved issues, such as whether the mechanism results from a mechanical impact or a natural increase in CSF accumulation in the SAS, such as may be seen in BESS. Increasing awareness of this disease in the general public has given impetus to the research into its cause. The present study therefore attempted to elucidate these issues through an analysis of the findings of a case series over the past ten years.

2. Materials & Methods

Between 2013 and 2023, 51 patients aged < 2 years were referred to the Department of Neurosurgery at Bethlehem Garden Hospital with symptoms attributable to a subdural hematoma and fluid collection. The full clinical data on these patients, including their CT and MRI findings and interview records, were analyzed. Eighteen of the patients received a diagnosis of acute subdural hematoxygroma (ASDHy) on the basis of their clinical history and brain imaging studies. MRI, including susceptibility-weighted (SWI) imaging and T2* sequences, confirmed the absence of a primary brain parenchymal injury. All the patients were reported to a child care center where the result of their medical assessment excluded any suspicion for the possibility of shaken baby syndrome (SBS) or abusive head trauma (AHT). Patients with an underlying bleeding diathesis were also excluded.

ASDHy consists of a mixture of blood and CSF (or CSF-like fluid) which induces the acute onset of symptoms and signs when it accumulates in the subdural space [1]. For the purpose of this study, BESS was defined by a minimum distance of 5 mm between the brain surface and the inner table of the skull [5]. A large sylvian fissure was defined as previously [6-8].

3. Results

Clinical results

Eighteen patients comprising eight males and ten females with a median age at diagnosis of 3.8 months (range: 2-10 months) were enrolled. Fifteen patients (83%) were younger than 4 months, four patients showed symptoms and signs after a low fall, and 13 (72%) had no history of head trauma. All the patients presented with an acute symptom onset, including generalized convulsive seizures (n=11) and repeated vomiting (n=2). Five patients had repeated vomiting followed by seizures.

Varying degrees of retinal hemorrhage, bilateral lesions, and unilateral lesions were observed in 14, 11, and 3 patients, respectively. Two patients, including one with poor seizure control and one with altered consciousness status, required subdural drainage to treat these conditions. Sixteen patients (89%) were conservatively managed. All 18 patients achieved a favorable outcome on a follow-up examination (3 months to 9 years 2 months; mean: 3 years 5 months). No recurrence of the subdural fluid collection occurred during the study period.

Neuroimaging results

On fluid-attenuated inversion recovery (FLAIR) or susceptibility-weighted imaging (SWI) MRI, ASDHy appeared as a large fluid collection between the dura and arachnoid membranes with an intensity higher than that of the CSF. The ASDHy was bilateral in all the patients and covered both cerebral hemispheres. The ASDHy was more pronounced on the right side in eight patients, on the left side in two patients, and was roughly equal in eight patients. BESS was found in 15 patients (83%). All the patients presented with a large sylvian fissure (LSF); in 17 patients (94%) it was more pronounced on the left side and in one patient (5%) it was roughly equal on both sides. MRI, including SWI and T2* sequences, revealed no primary cerebral parenchymal injury. Moreover, no complex subdural hematoma was observed.

Table 1 presents a summary of the patients' clinical profiles.

Table 1. Summary of the clinical profiles of the 18 patients with infantile acute subdural hematoxygroma.

Case No	Age (mos) M/F	Presenting signs & symptoms	History of trauma	Management	Retinal hemorrhage	Imaging findings			Outcome (follow-up)
						ASDHy	BESS	LSF	
1	10M	Seizure	Low fall	Conservative	None	Bilateral R>L	(+)	(+) L>R	GR 9y2m
2	3F	Vomiting, seizure	None	Conservative	Bilateral	Bilateral L=R	(+)	(+) L>R	GR 4y8m
3	7F	Seizure	Low fall	Conservative	Bilateral	Bilateral L=R	(+)	(+) L>R	GR 4y3m
4	2M	Vomiting, seizure, tense fontanel	None	Conservative	Bilateral	Bilateral R>L	(+)	(+) L>R	GR 4y3m
5	4F	Vomiting	Fall from bed (50 cm in height)	Conservative	Bilateral	Bilateral L=R	(-)	(+) L>R	GR 4y0m

Case No	Age (mos) M/F	Presenting signs & symptoms	History of trauma	Management	Retinal hemorrhage	Imaging findings			Outcome (fol-low-up)
						ASDHy	BESS	LSF	
6	5F	Seizure	None	Conservative	Bilateral	Bilateral L=R	(+)	(+) L>R	GR 4y0m
7	4F	Seizure	Fall from sister's hands (30 cm in height)	Subdural drainage	Bilateral	Bilateral L=R	(+)	(+) L>R	GR 3y7m
8	8M	Seizure	Low fall	Conservative	Bilateral	Bilateral L>R	(+)	(+) L>R	GR 3y7m
9	3M	Seizure	None	Conservative	Bilateral	Bilateral R>L	(-)	(+) L>R	GR 3y10m
10	2M	Vomiting	None	Conservative	Unilateral left	Bilateral L>R	(+)	(+) L>R	GR 10m
11	4F	Seizure	None	Conservative	None	Bilateral R>L	(+)	(+) L>R	GR 11m
12	3F	Seizure	None	Conservative	None	Bilateral L=R	(+)	(+) L>R	GR 9m
13	2M	Seizure	None	Conservative	None	Bilateral L=R	(+)	(+) L=R	GR 8m
14	4F	Vomiting	None	Subdural drainage	Unilateral right	Bilateral R>L	(-)	(+) L=R	GR 1y4m
15	3M	Seizure	None	Conservative	Bilateral	Bilateral R>L	(+)	(+) L>R	GR 4m
16	4F	Vomiting, seizure	None	Conservative	Unilateral right	Bilateral R>L	(+)	(+) L>R	GR 3m
17	3M	Seizure, macrocrania	None	Conservative	Bilateral	Bilateral R>L	(+)	(+) L>R	GR 3m
18	2F	Vomiting	None	Conservative	None	Bilateral R=L	(+)	(+) L>R	GR 1y

Abbreviations ASDHy: acute subdural hematoxygroma, BESS: benign enlargement of subarachnoid space LSF: large sylvian fissure GR: good recovery

L: left R: right

4. Case Series

Case 1 (Patient 4)

A 2-month-old, male patient with no history of head trauma who was born at full term had a two-day history of intermittent vomiting followed by generalized convulsions. The patient was taken to the emergency department of a local hospital, where altered consciousness status and tense fontanel were noted. Computed tomography findings led to a diagnosis of subdural fluid collection by a pediatrician

(Figure 1, left).

On admission, an ophthalmological examination revealed bilateral retinal hemorrhages (RH). After admission for observation, the patient was reported to a child care center, which ruled out AHT as the cause of his condition. His clinical course was uneventful, and MRI on hospital day 4 found bilateral ASDHy (Figure 1, right). Follow-up MRI 19 days later demonstrated a decrease in the ASDHy and no cerebral parenchymal abnormalities. Outpatient follow-up over five months confirmed normal development without any neurological deficit.

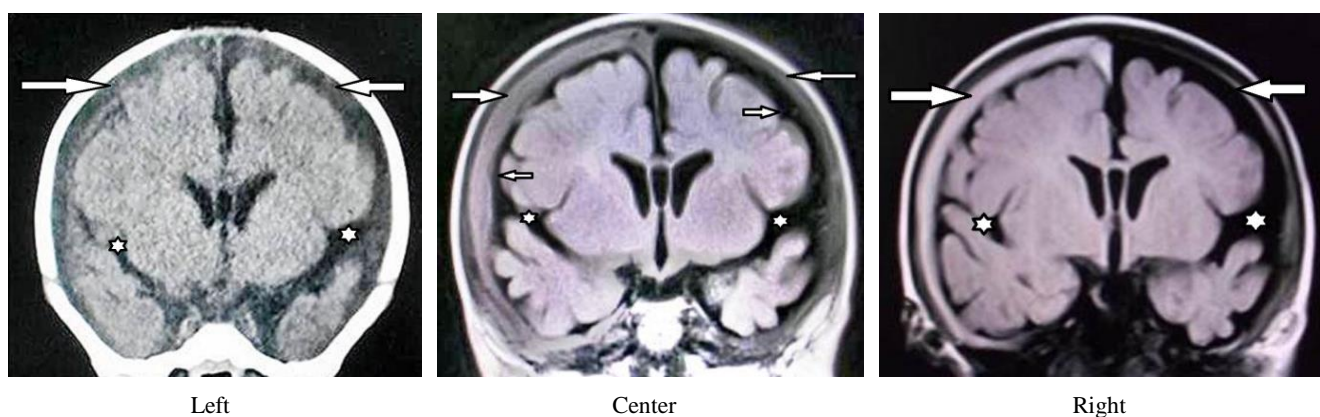


Figure 1. Case 1 (No. 3), female aged 2 months; Left: CT, coronal view on arrival demonstrating large, bilateral, extra-axial fluid collections. The hyperintensity was slightly greater on the right side than in the CSF. (arrows); Note the large, bilateral sylvian fissures. (R>L, stars); Center: Coronal view on magnetic resonance imaging (fluid-attenuated inversion recovery, FLAIR) three days after onset showing a bilateral area of higher signal intensity in the extra-cerebral fluid collections than in the CSF, indicating ASDHy. BESS was also observed (R>L, small arrows). Note the large, bilateral sylvian fissures on both sides (R>L, stars). No mass effect or parenchymal abnormality was observed on the other sequences (not shown). Right: Coronal view on MRI (FLAIR) 21 days after onset showing decreased ASDHy (arrows). Note the large, bilateral sylvian fissure (R>L, star).

Case 2 (Patient 5)

A 4-month-old, female infant with a history of acute bronchiolitis at the age of 2 months fell from her bed and struck the occipital region against a tatami mat. She began crying immediately and then experienced two episodes of projectile vomiting. On the next afternoon, she was taken to a local hospital for repeating vomiting. Tense fontanel was noted, and CT demonstrated extra-cerebral fluid collections (Figure 2, left) prompting an ophthalmological examination,

which found bilateral retinal hemorrhages (RH). She was hospitalized for further observation and was reported to a child care center, which ruled out AHT as the cause of her condition. MRI 12 days later revealed a decrease in the ASDHy (Figure 2, center). During a 14-day period of observation at the hospital, the patient remained asymptomatic and was eventually discharged. Outpatient follow-up over five months, including CT, confirmed normal development and ASDHy resolution (Figure 2, right).

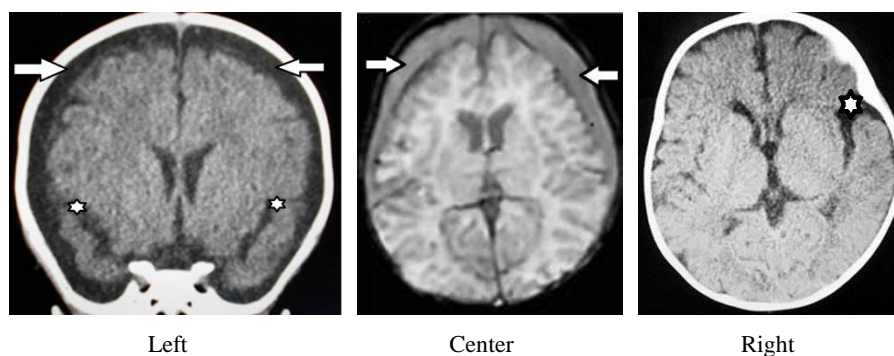


Figure 2. Case 2 (No. 5), female aged 4 months. Left: Coronal view on CT on admission demonstrating large, bilateral, extra-cerebral fluid collections indistinguishable from CSF (arrows). Note the large, bilateral sylvian fissures (stars). Center: Axial view on MRI (SWI) 12 days after onset demonstrating an area of higher signal intensity in the extra-cerebral fluid collections than the CSF, indicating ASDHy. No mass effect or parenchymal abnormality was observed on the other sequences (not shown). Right: CT at post-onset month 5 demonstrating bilateral resolution of ASDHy and residual LSF on the left side (star).

Case 3 (Patient 9)

An 8-month-old, male infant with no significant medical history exhibited signs of altered consciousness status and an upward gaze, which were noticed by the mother while she was changing his diapers. After tonic convulsion developed, the patient was taken to the emergency department of a local

hospital, where a physician noticed status epilepticus associated with tense fontanel. Emergency CT revealed bilateral ASDHy (Figure 3, left). The patient was given medications but was otherwise managed with a wait-and-see strategy.

On day 2, the seizures appeared well controlled with anticonvulsants, and MRI revealed a bilateral ASDHy associ-

ated with BESS and LSF (Figure 3, right). Fundoscopy demonstrated bilateral retinal hemorrhages. Four days later, the patient achieved full recovery and was discharged home with oral anticonvulsants 20 days after the onset of her seizures. During hospitalization, the patient was reported to a child care center, which ruled out AHT as the cause of her condition. A follow-up examination at the age of 3 years and 1 month found normal neurological development.

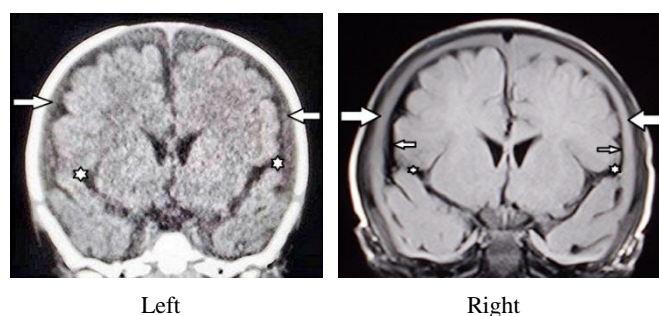


Figure 3. Case 3 (No 9), male aged 6 months. Left: CT (coronal view) on arrival demonstrating bilateral, extra-axial fluid collections with slightly higher intensity than the CSF in the lateral ventricles, indicating ASDHy (arrows). Note the large, bilateral sylvian fissures and the slightly larger size on the left side (stars). Right: MRI (FLAIR, coronal view) obtained 2 days later demonstrating bilateral ASDHy (arrows). Note the large, bilateral sylvian fissures (L>R, star) and bilateral enlargement of the SAS, which is more pronounced on the left side (small arrows). No parenchymal abnormality was found on the other sequences (not shown).

Case 4 (Patient 13)

A 2-month-old, male patient born after an uneventful delivery and with no significant medical history experienced vomiting and myoclonus-like movement of the right hand while being breastfed at home (seen on video). The infant was taken to the emergency department of a local hospital, where a pediatrician found no abnormality.

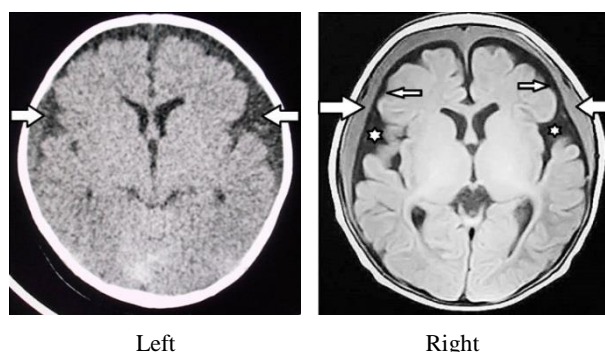


Figure 4. Case 4 (No. 13), male aged 2 months. Left: CT on arrival demonstrating bilateral, extra-axial fluid collections (arrows). Right: MRI (FLAIR, axial view) demonstrating bilateral ASDHy (arrows). Note the BESS (small arrows) and LSF (stars). No mass effect or intraparenchymal abnormality was observed on the other sequences (not shown).

On the way to home, however, the infant began to exhibit myoclonus-like movements and became febrile. He was hospitalized at the previous hospital, where CT demonstrated bilateral, extra-axial fluid collections (Figure 4, left). MRI on the same day demonstrated a large ASDHy, BESS, and LSF on both sides (Figure 4, right). Ophthalmological examination found no retinal hemorrhage or other abnormality. During hospitalization for close observation, the patient was reported to a child care center, which ruled out AHT as the cause of his condition. The patient was followed for 11 months at the outpatient clinic, where normal developmental milestones was confirmed.

5. Discussion

All the patients in this series experienced seizures and/or repeated vomiting as the presenting signs and symptoms, which led to the diagnosis of ASDHy. The benign clinical course accompanied by seizures and retinal hemorrhages in ASDHy is almost identical to that of infantile acute subdural hematoma (IASDH) [9, 10]. In particular, mild IASDH, which in most cases involves retinal hemorrhages and rapid recovery without treatment, should be included in the differential diagnosis of ASDHy [11, 12].

The most important pathology associated with SBS and AHT is encephalopathy, which in this context usually occurs as a primary cerebral parenchymal injury, such as a brain contusion or diffuse, axonal injury [1]. In contrast, all the infants with ASDHy in the present series differed from those with SBS or AHT in having no primary cerebral parenchymal injury. Currently in Japan, healthcare workers are required by law to report any patients with suspected symptoms of child abuse to a childcare center. During hospitalization for close observation, all infantile patients are assessed in accordance with the recommended protocol, which includes precise history taking and ascertaining the family composition and contacts. This information is communicated to a child care center where a flow chart is then created to assess for AHT. All the patients in the present series were reported to a childcare center, which ruled out AHT [13].

CT findings on admission showing large, extra-axial fluid collections may make it difficult to differentiate between BESS and chronic subdural hematoma [14]. However, the presence of neomembranes on MRI, particularly on FLAIR imaging, provides an important criterion for distinguishing chronic subdural hematoma from ASDHy [1]. The etiology of ASDHy in the context of BESS is poorly understood but presumably lies in the anatomical stress on the arachnoid membrane and blood vessels in the enlarged SAS [15].

The current hypothesis of the pathogenesis of ASDHy holds that stretching of the bridging veins in the subdural space caused by an enlargement of the CSF spaces creates a predisposition to the development of a subdural hematoma. Based on their observations, McNeely et al. reported that subdural hematomas may occur either spontaneously or as result of minor or unnoticed trauma in patients with BESS [5].

Lee et al. reported that when patients with BESS suffer head trauma, the brain is more easily displaced and to a greater degree than seen in normal individuals because the larger SAS enables greater brain mobility. Due to the buffering effect of the enlarged SAS, the brain does not directly contact the skull and is therefore less likely to be damaged from external impacts. On the other hand, because the bridging veins are more prone to stretching and are torn by violent brain movements, a subdural hematoma or subdural fluid collection arising from tearing of the arachnoid membrane is more likely [4]. Thus, the presence of BESS is considered a significant precondition for the development of a subdural hematoma or subdural fluid collection. In fact, using a mathematical model of the cranial vault to demonstrate the relationship between venous stretching and the width of the extra-axial spaces, Papasian and Frim found that even very minor trauma has the potential to predispose patients with BESS to subdural hemorrhaging [15].

In the present series, both BESS and LSF were found to contribute to increased cranio-cerebral disproportion (CCD), which can induce arachnoid tearing and rupture of the bridging veins. There are no previous studies focusing on LSF, but this anatomical predisposition should be considered a risk factor of subdural hematoma or subdural fluid collection development.

As noted in previous reports, ASDHy in infants is a self-limiting disorder having a benign clinical course in most cases [4, 16, 17]. However, a minority of patients, such as those in Cases 1 and 3 in the present case series, requires surgical intervention. If appropriate treatment, including subdural drainage, is not performed soon after the onset of impaired consciousness status or severe convulsions, these patients may incur permanent, neurological deficits. Before this situation develops, particularly during early infancy, percutaneous subdural tapping as prescribed for IASDH [9] is recommended (Figure 5).

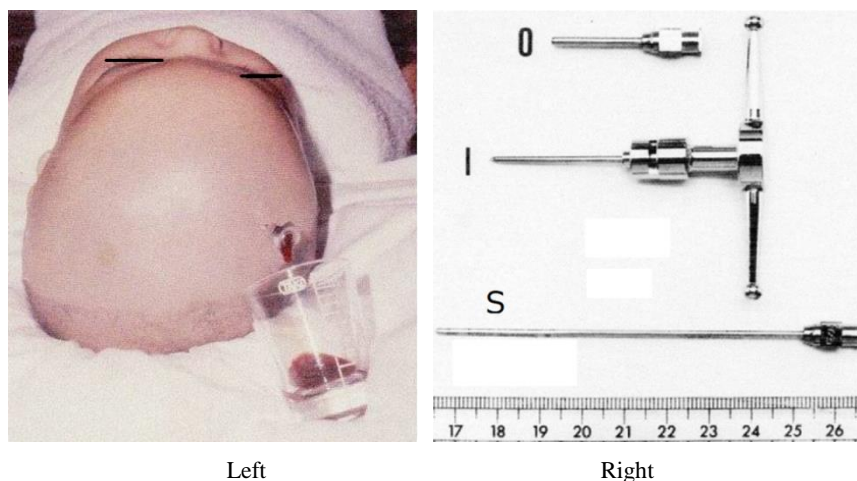


Figure 5. Percutaneous subdural tapping (this case not included in the series). Left: Subdural tapping, irrespective of cranial sutures, was performed through the skull at the largest part of the subdural hematoma under local anesthesia. Right: Three parts of the needle assembly devised for the percutaneous subdural tapping (Aoki subdural needle for infants, manufactured by Muraishi Iryoki Co., Ltd., Tokyo, Japan). If drainage is hampered by a partially clotted hematoma, the obstruction of the outer needle is released with a stylet needle. O: outer needle, I: inner needle, S: stylet needle.

Furthermore, although most ASDHy cases involve bilateral lesions, unilateral treatment may be sufficient to eradicate bilateral subdural hematomas and effusion [18, 19]. Such less invasive management strategies may be clinically useful for the treatment of subdural hematomas and fluid collections in infants.

The remarkably high frequency (94%) of left-sidedness of the LSF in the present series is noteworthy because ASDHy is typically more pronounced on the right side. This paradoxical phenomenon might provide clues to the mechanism underlying the rupture of the arachnoid membranes and bridging veins in patients with CCD. In addition, LFS is thought to contribute to increasing the rotational force of the brain during an occipital impact because the loose fixation of temporal

lobe at the middle cranial fossa and the sphenoid ridge allows greater brain mobility. The rotation occurring under these conditions is thought to cause stretching of the bridging veins and result in their rupture.

6. Conclusions

Most cases of ASDHy develop in early infancy, involve retinal hemorrhages, and have a benign clinical course. In infants with CCD, tearing of the arachnoid membrane, either spontaneously or following a head impact, is associated with rupturing of the adjacent vessels, causing a mixture of blood and CSF to flow into the subdural space. As with BESS, which is a possible predisposing factor of ASDHy, LSF in-

creases CCD, thus raising the risk of an arachnoid tear. If subdural drainage is required, percutaneous subdural tapping is recommended as a less invasive method, particularly in very young infants.

Limitations

The present study has several limitations. The patients were all Japanese infants who were referred to the study center for a second opinion. Therefore, the findings may not be generalizable to infants of other ethnic backgrounds. Moreover, all the patients in this series were managed on an emergency basis, thus potentially introducing a selection bias.

Issues warranting further study include the pathophysiological relationship between BESS and LSF, and more globally important, clarifying the presence or absence of a primary cerebral parenchymal injury in patients with SBS or AHT [10].

Ethics Approval and Consent to Participate

This article was approved by the ethics committee of Bethlehem Garden Hospital and Tokyo Metropolitan Tama Medical Center. No funding was obtained for this study. The parents/legal guardians provided consent to publish the case details in this study.

Consent to Publish

The author gives his consent to the journal to publish the identifiable details, including photographs and case details, contained in the manuscript.

Author's Contribution

Nobuhiko Aoki (corresponding author with no coauthors) conceived the idea of the study, conducted the literature search, and drafted the original manuscript.

The author has reviewed the manuscript draft and revised it critically for intellectual content and approved the final version of the manuscript to be published.

Data Availability Statement

None of the data or material in this study is available for viewing.

Conflicts of Interest

The authors declare no conflicts of interest.

References

- [1] Wittschieber B, Karger D, Pfeiffer H. Understanding Subdural Collections in Pediatric Abusive Head Trauma 2019 40: 388-395.
- [2] Aoki N. Extracerebral fluid collections in infancy: Role of magnetic resonance imaging in differentiation between subdural effusion and subarachnoid space enlargement J Neurosurg 1994 81: 20-23.
- [3] Lee HC, Chong S, Lee JY. Benign extracerebral fluid collection complicated by subdural hematoma and fluid collection: clinical characteristics and management. Childs Nerv Syst. 2018 34: 235-45.
- [4] Lee KS. The pathogenesis and clinical significance of traumatic subdural hygroma. Brain Inj. 1998 12: 595-603.
- [5] McNeely PD, Atkinson JD. Subdural Hematomas in Infants with benign enlargement of the subarachnoid spaces are not pathognomonic for child abuse AJNR Am J Neuroradiol. 2006 27: 1725-28.
- [6] Pedersen H. Measurement of the normal ventricular system and supratentorial subarachnoid space in children with computed tomography. Neuroradiology 1979 17: 231-237.
- [7] Fukuyama Y, Miyao M, Ishizu T. Developmental changes in normal cranial measurements by computed tomography. Develop med child neurol. 1979 21: 425-432.
- [8] Hussain ZB, Hussain AD, Mitchell B. Extra-axial cerebrospinal fluid spaces in children with benign external hydrocephalus: A case control study. Neuroradiol J. 2017 30: 410-417.
- [9] Aoki N, Masuzawa H: Infantile acute subdural hematoma: Clinical analysis of 26 cases. J Neurosurg 1984 61: 273-280.
- [10] Aoki N Infantile acute subdural hematoma: caused by abuse or mild head trauma? Nerv Syst Children (Japanese) 2011 36: 326-330.
- [11] Aoki N: 2023 Clinical and neuroimaging characteristics in mild-type infantile acute subdural hematoma. Report of four cases Childs Nerv Syst 2023. <https://doi.org/10.1007/s00381-023-06089-7>
- [12] Aoki N: Infantile Acute Subdural Hematoma with retinal hemorrhage caused by minor occipital impact witnessed by an ICU nurse: a case report. Pediatr Neurol Neurosci 2020 4(1): 47-50, 2020.
- [13] Shimoji K, Suehiro E, Matsuno A, Araki T. Abusive head trauma in Japan. Childs Nerv Syst 2022 Oct4. <https://doi.org/10.1007/s00381-022-05692-44>
- [14] Aoki N. Chronic subdural hematoma in infancy. Clinical analysis of 30 cases in the CT era. J Neurosurg 1990 73: 201-205.
- [15] Papasian NC, Frim DM. Theoretical model of benign external hydrocephalus that predicts a predisposition towards extra-axial hemorrhage after minor head trauma Pediatr Neurosurg 2000 33: 188-93.

- [16] Scheller J, Wester K: Is external hydrocephalus a possible differential diagnosis when child abuse is suspected? *Acta Neurochirurgica* 2021. <https://doi.org/10.1007/s00701-021-04786-3>
- [17] Tsubokawa T, Nakamura S, Satoh K. Effect of temporary subdural-peritoneal shunt on subdural effusion with subarachnoid effusion *Childs Brain*. 1984 11(1): 47-59.
- [18] Aoki N Unilateral subdural-peritoneal shunting for bilateral chronic subdural hematomas in infancy *J Neurosurg* 1985 63: 134-137.
- [19] Aoki N, Masuzawa H. Bilateral chronic subdural hematomas without communication between the hematoma cavities: treatment with unilateral subdural-peritoneal shunt. *Neurosurgery* 1988 22: 911-913.